



# I NET “rari”



Bari,  
7-10 novembre 2013

## NET del tratto uro-genitale



*Antonio Bianchi*

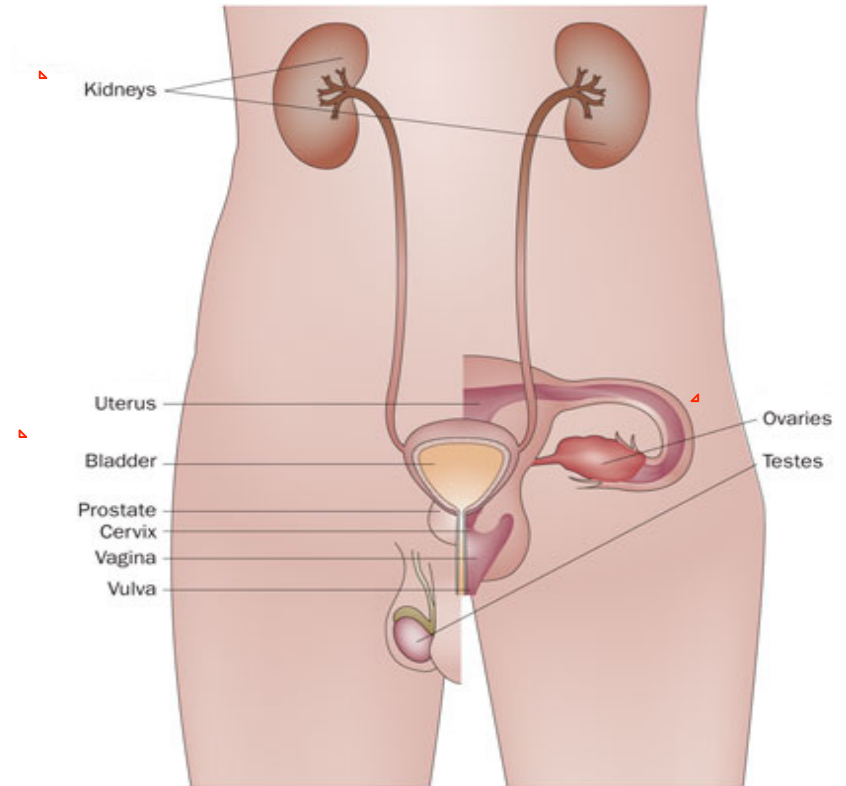
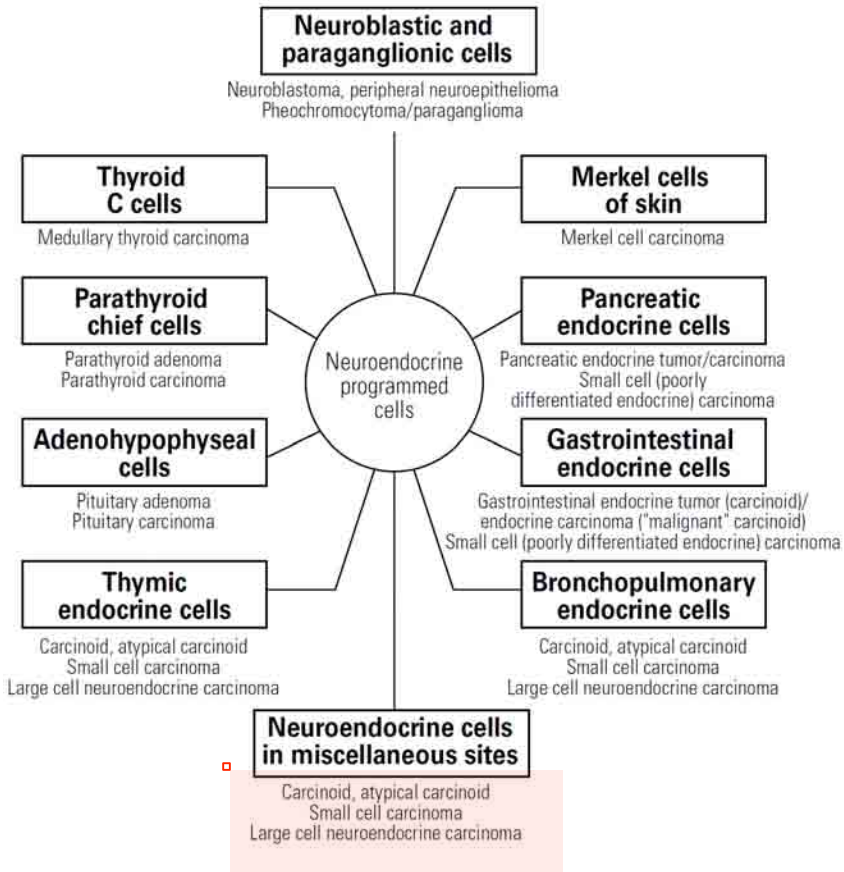
Divisione di Endocrinologia

Policlinico Universitario “Agostino Gemelli”

Università Cattolica del Sacro Cuore

Roma

# NET of the genitourinary tract





# NET of the genitourinary tract



Bari,  
7-10 novembre 2013

## Typical carcinoid

A tumour with carcinoid morphology and less than 2 mitoses per 2 mm<sup>2</sup> (10 HPF), lacking necrosis and 0.5 cm or larger

## Atypical carcinoid

A tumour with carcinoid morphology with 2-10 mitoses per 2 mm<sup>2</sup> (10 HPF) OR necrosis (often punctate)

## Large cell neuroendocrine carcinoma

1. A tumour with a neuroendocrine morphology (organoid nesting, palisading, rosettes, trabeculae)
2. High mitotic rate: 11 or greater per 2 mm<sup>2</sup> (10 HPF), median of 70 per 2 mm<sup>2</sup> (10 HPF)
3. Necrosis (often large zones)
4. Cytologic features of a non-small cell carcinoma (NSCLC): large cell size, low nuclear to cytoplasmic ratio, vesicular, coarse or fine chromatin, and/or frequent nucleoli. Some tumours have fine nuclear chromatin and lack nucleoli, but qualify as NSCLC because of large cell size and abundant cytoplasm.
5. Positive immunohistochemical staining for one or more NE markers (other than neuron specific enolase) and/or NE granules by electron microscopy.

## Small cell carcinoma

Small size (generally less than the diameter of 3 small resting lymphocytes)

1. Scant cytoplasm
2. Nuclei: finely granular nuclear chromatin, absent or faint nucleoli
3. High mitotic rate (11 or greater per 2 mm<sup>2</sup> (10 HPF), median of 80 per 2 mm<sup>2</sup> (10 HPF)
4. Frequent necrosis often in large zones



# NET of the genitourinary tract are rare!



Bari,  
7-10 novembre 2013

▫ Niigata Registry (1953-2002): Analysis of 11842 Reported Cases

▫ **Table II - Organ distribution of the carcinoid group and variant group**

<b>Organ/Site</b>	<b>Carcinoid group: No. / %</b>	<b>Typical No. / %</b>	<b>Atypical No. / %</b>	<b>T/A</b>	<b>Variant group No. / %</b>	<b>Overall No. / %</b>
Digestive system	6933/ 64.2	6409/ 68.0	524/ 38.1	12.2	486/ 46.8	7419/ 62.6
Extradigestive system	3871/ 35.8	3021/ 32.0	850/ 61.9	3.6	552/ 53.2	4423/ 37.4
Respiratory system	2143/ 19.8	1760/ 18.7	383/ 27.9	4.6	130/ 12.5	2273/ 19.2
Mediastinum/thymus	501/ 4.6	415/ 4.4	86/ 6.3	4.8	18/ 1.7	519/ 4.4
Breast	206/ 1.9	105/ 1.1	101/ 7.4	1.0	125/ 12.0	331/ 2.8
Ovary	352/ 3.3	336/ 3.6	16/ 1.2	21.0	1/ 0.1	353/ 3.0
Larynx	241/ 2.2	42/ 0.4	199/ 14.5	0.2	44/ 4.2	285/ 2.4
Uterine cervix	85/ 0.8	51/ 0.5	34/ 2.5	1.5	132/ 12.7	217/ 1.8
Middle ear	72/ 0.7	55/ 0.6	17/ 1.2	3.2	5/ 0.4	77/ 0.7
Kidney	60/ 0.6	57/ 0.6	3/ 0.2	19.0	14/ 1.3	74/ 0.6
Testicle	70/ 0.7	70/ 0.7	0/ 0.0	–	0/ 0.0	70/ 0.6
Urinary bladder	22/ 0.2	19/ 0.2	3/ 0.2	6.3	56/ 5.4	78/ 0.7
Sites unspecified**	119/ 1.1	111/ 1.2	8/ 0.6	13.9	27/ 2.6	146/ 1.2
<b>Overall/ average</b>	<b>10804/100.0</b>	<b>9430/100.0</b>	<b>1374/100.0</b>	<b>6.9</b>	<b>1038/100.0</b>	<b>11842/100.0</b>

\* Including 106 cases in Meckel's diverticulum. \*\* Including 20 in the retroperitoneal region, 16 in the uterine body, 11 in the skin and 9 in the prostate.  
T/A: Ratio of typical & atypical carcinoids.



# Renal Carcinoid



Bari,  
7-10 novembre 2013

## Epidemiology/etiology/histological type/clinical presentation/prognosis

- ✓ **Rare**; association with teratoma (18%), horseshoe kidney (14%), polycystic kidney disease (2%)
- ✓ About 100 cases described in literature (first report in 1966); no gender preference
- ✓ Mean age at diagnosis: 49 (13-79)
- ✓ **Histological types**: typical histologic features of carcinoids in other organs of the body.
- ✓ **Presentation**: incidental, no specific finding on computed tomography (CT) or magnetic resonance imaging (MRI), abdominal, back or flank pain, mass (1,5-30 cm), haematuria, anemia. Carcinoid syndrome symptoms are uncommon (<10%). Octreotide scintigraphy more useful than FDG-PET.
- ✓ **The clinical outcome** is difficult to predict and a significant proportion of patients with metastatic disease (50% of cases, lymphnodes, liver and bone) have a protracted clinical course.



# Neuroendocrine carcinoma (NEC) of the kidney



Bari,  
7-10 novembre 2013

## Epidemiology/etiology/histological type/clinical presentation/prognosis

- ✓ 1% of all epithelial renal malignancies
- ✓ **Average age:** 60 years, with no sex predilection.
- ✓ **Histological types:** nests and trabecula of poorly-differentiated small, round to fusiform cells; a concomitant urothelial carcinoma is common
- ✓ **Presentation:** Abdominal pain and gross haematuria are the most frequent clinical symptoms
- ✓ **The prognosis is poor** and stage dependent. At least, 75% of patients die of their disease within one year regardless of treatment.



# Bladder Carcinoid



Bari,  
7-10 novembre 2013

## Epidemiology/Etiology/Histological type/clinical presentation/prognosis

- ✓ **Rare:** less than two-dozen cases of carcinoid tumours of the urinary bladder have been reported
- ✓ **Elderly patients** (mean age, 56 years; range, 29-75 years), with slight male predominance
- ✓ **Presentation:** hematuria is the most common clinical presentation, followed by irritative symptoms. Association with carcinoid syndrome has not been reported.
- ✓ **Histologically** similar to their counterparts in other organ sites, these tumours are submucosal with a predilection for the trigone and bladder neck. The tumour often presents as a polypoid lesion (3-30 mm). Coexistence of carcinoid with other urothelial neoplasia has been reported.
- ✓ **Differential diagnosis:** paraganglioma, urothelial carcinoma and metastatic prostatic carcinoma.
- ✓ **Prognosis:** more than 25% of patients with pure carcinoid will have regional lymph node or distant metastasis but majority are cured by excision.



Bari,  
7-10 novembre 2013

# Testicular Carcinoid

## Epidemiology/Etiology/Histological type/clinical presentation

- ✓ **Rare**; 0.5-0.6% of all carcinoid tumors; 0.1-0.2 % of testicular neoplasm
- ✓ **About 100 cases** described in literature
- ✓ **Mean age at diagnosis**: 46 years (range 10-84)
- ✓ **Histological types**: pure or primary (insular and trabecular), associated with teratoma, secondary metastatic to the testis
- ✓ **Presentation**: incidental, testicular mass (10-95 mm) or diffuse testicular enlargement. More common in the left, infrequently metastasizes, rarely with carcinoid syndrome (1-10%)





# Testicular Carcinoid



Bari,  
7-10 novembre 2013

## Prognosis

- ✓ Correlated with tumor staging
- ✓ **The critical issue in determining therapy for testicular carcinoids is the demonstration of metastatic disease.**
- ✓ In localized cases (90.8% of those reported), orchiectomy is usually curative, while those who presented with metastatic disease (9.2%) had a more severe, unsuccessful clinical course with an average survival time of 2 years



# Ovarian Carcinoid



Bari,  
7-10 novembre 2013

## Epidemiology/Etiology/Histological type

- ✓ **Rare**; 0.5-3% of all carcinoid tumors; 0.1% of ovarian neoplasm
- ✓ About 500 cases described in literature
- ✓ **Mean age at diagnosis: 55 years (range 14-83)**
- ✓ histological types: insular, stromal, mucinous and trabecular; isolation or accompanied by dermoid cyst, mucinous cystic tumor or a Brenner tumor; mostly associated with teratoma



# Ovarian Carcinoid



Bari,  
7-10 novembre 2013

## Clinical presentation

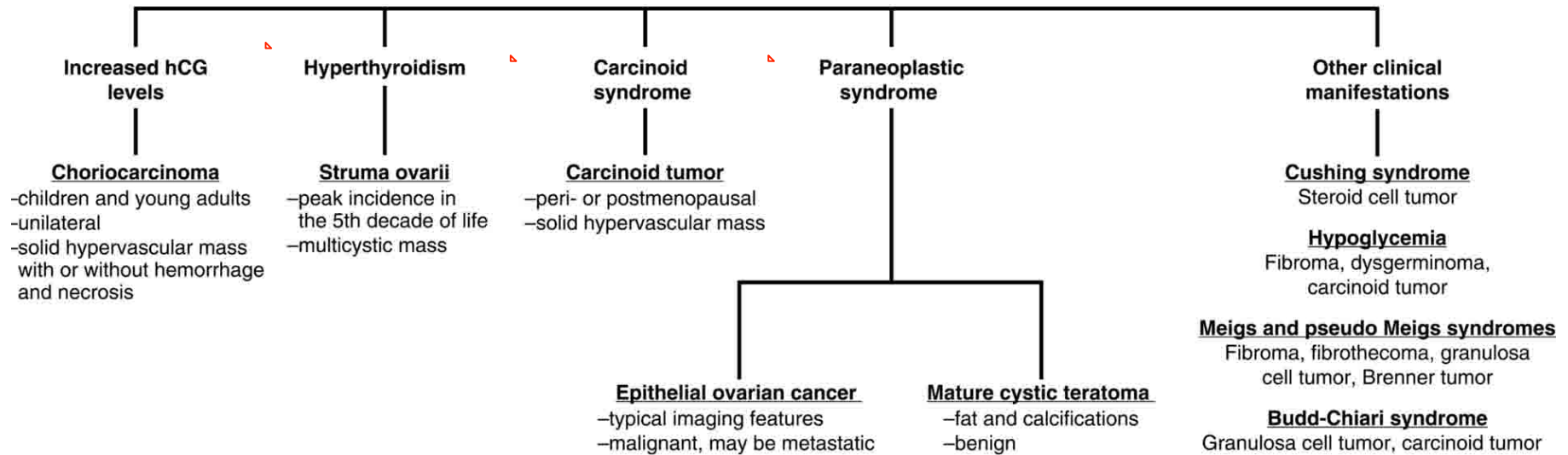
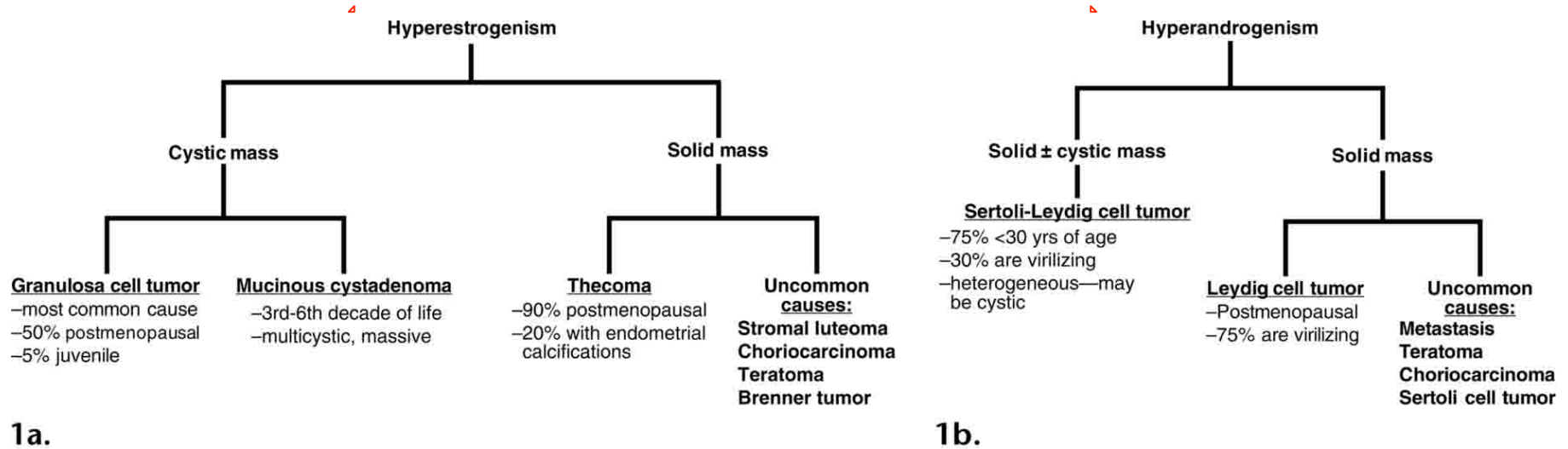
- ✓ abdominal pain; incidentally, during clinical/radiological/histopathological examination
- ✓ pelvic mass
- ✓ severe constipation (peptide YY)
- ✓ hirsutism (peptide YY, ++trabecular, androgens)
- ✓ Carcinoid syndrome → ~ 30% of patients (++insular)
- ✓ 23 cases of carcinoid heart disease reported in the literature



# Clinical syndromes associated with ovarian neoplasms



Bari,  
7-10 novembre 2013





# Ovarian Carcinoid



Bari,  
7-10 novembre 2013

## Prognosis

- ✓ ~66% of cases: localized lesions (confined to ovary)
- ✓ 22-31% of cases: distant spread (evidence of metastases to other organs)
- ✓ prognosis favorable (~90% 5 years of survival rate with localized lesions)



# Neuroendocrine carcinomas (NEC) of the ovary



Bari,  
7-10 novembre 2013

## Small cell (SC) NEC

- ✓ About 300 cases reported
- ✓ Hypercalcaemic type: undifferentiated carcinoma that is usually associated with paraendocrine hypercalcaemia (2/3) and is composed primarily of small cells.
- ✓ Pulmonary type: small cell carcinoma resembling pulmonary small cell carcinomas of neuroendocrine type

## Large cell (LC) NEC

- ✓ Rare (35 cases) malignant tumour composed of large cells that show neuroendocrine differentiation.



# Conclusions



Bari,  
7-10 novembre 2013

- ✓ **Two types of rare NET** with diverse clinicopathological features and outcome are identified in the **urinary system and genital organs**: **carcinoid tumour and neuroendocrine carcinoma (NEC)**. Both show the morphology and immunophenotype of NET originating in other organs
- ✓ The **prognosis** of carcinoid is favorable in localized lesions, but metastases can be detected at the initial evaluation and they have been reported up to several years after removal, emphasizing the need for a long-term follow-up. NEC includes small cell carcinoma (SCC) and large cell NE carcinoma (LCNEC), the latter being exceedingly rare. Although the occurrence is very rare, it is highly aggressive.
- ✓ **The endocrinologist must learn to recognize these tumors and to treat them as part of a multidisciplinary approach**



Bari,  
7-10 novembre 2013

***GRAZIE!***

***RINGRAZIAMENTI al NET/RT-Team***

***Policlinico A. Gemelli***

***Roma***

